

## Middle ear status in ears showing high admittance tympanograms. Clinical value of the use of the two-component 678 Hz oto-admittance tympanogram

G. De Ceulaer, Th. Somers, F. E. Offeciers and P. J. Govaerts

University Department of Otolaryngology St. Augustinus Hospital, Antwerp-Wilrijk, Belgium

**Key-words.** High frequency tympanometry ; conductance ; susceptance ; hearing tests ; hearing-impaired persons ; hearing loss

**Abstract.** Middle ear status in ears showing high admittance tympanograms. Clinical value of the use of the two-component 678 Hz oto-admittance tympanogram. The present paper reports on the results of a retrospective study using 678 Hz susceptance-conductance tympanometry performed on abnormally high admittance middle ears. High admittance was proven to be caused by (partial) disruption or lysis of the ossicular chain. Retrospective analysis shows that 678 Hz tympanometry seems to be more accurate in the differential diagnosis of ossicular chain disruptions compared to CT-imaging of the ossicular chain (88% versus 81% correct identification respectively). Classic tympanometry using a probe frequency of 226 Hz was abnormal in only 43% of the cases.

### Introduction

In common audiologic practice, the evaluation of the middle ear status includes tympanometry and stapedal reflex measurements. These measures are mostly done using a low probe frequency, which is typically around 220 Hz (1).

There are many historic reasons why this frequency of 220 Hz became the standard probe frequency in immittance measurements: it is half of the well-known 440 Hz base tone used by musicians, there is no possible interference by the electrical mains frequency (50 Hz) and a resonance phenomenon in the external meatus is unlikely to occur at such a low frequency (1).

Furthermore, from the early results using the Zwislocki Bridge, it appeared that the resistive part (conductance G) of the admittance (Y) was clinically less important when compared to the reactive part (susceptance B). At low probe frequencies (e.g. 220 Hz), the admittance is dominated

by the susceptance and is more straightforward to interpret because the mass-factor of the susceptance is small (1).

Finally, a more practical reason for the manufacturers of impedance apparatus to opt for 220 Hz is the ease of microphone calibration of probes using this low probe frequency (1).

Many authors reported on the use of higher probe frequency tympanometry (2, 3). At higher probe frequencies the mass component of the susceptance of the tympano-ossicular system becomes more important. At higher frequencies the conductance (resistance) can also be measured with more precision. As a consequence it becomes more interesting not only to measure the susceptance component of the admittance, but to register and analyse both components simultaneously. All this results in more complicated B-G tympanograms compared to the simple bell-shaped 220 Hz admittance (Y) tympanograms (4, 5, 6).

It has been shown that these multicomponent (B and G) tym-

panograms at probe frequencies around 660 Hz can be important in the differential diagnosis of abnormally high-admittance tympano-ossicular systems due to ossicular luxation, disruption or lysis or due to a flaccid tympanum. In these cases the system becomes less stiffness-dominated as the mass factor becomes relatively more important. This results in multi-peaked B-G tympanogram patterns with abnormally large pressure intervals between the outer maxima. VANHUYSE *et al.* (4) theoretically explained the occurrence of various possible B-G tympanograms and CRETEN *et al.* (7) classified such multicomponent 660 Hz tympanograms in normal patterns and abnormal patterns based on normative values. These tympanograms at higher probe frequencies have proven to be more sensitive in the identification of ossicular disruptions (5).

The present retrospective study tries to evaluate the usefulness of 678 Hz multicomponent tympanometry and compare it with that of CT-imaging of the middle ear.

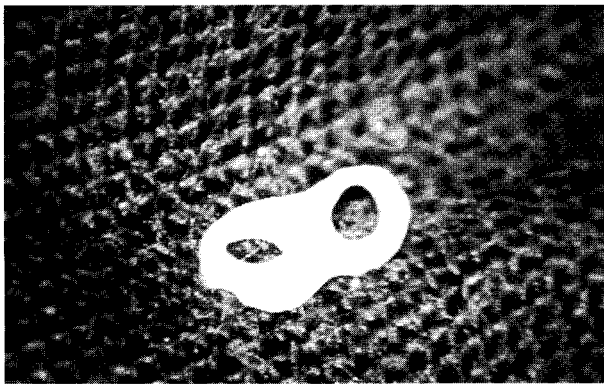


Fig. 1

Example of figure-8 implant material used in ossicular reconstruction surgery.

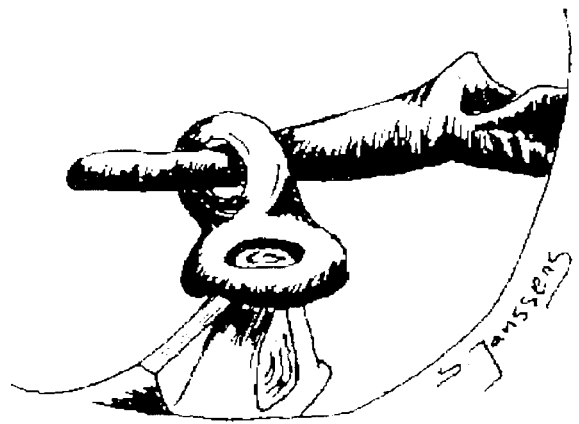


Fig. 2

Schematic representation of figure-8 incudoplasty according to Marquet.

## Material and method

All oto-admittance measures (admittance at 226 Hz and susceptance/conductance at 678 Hz) were done using a GSI 33 v2 middle ear analyser (Grason Stadler Inc., Milford USA). The probe was hermetically sealed in the earcanals by standard clinical probe tips. Susceptance and conductance were measured simultaneously in one pressure sweep. Pressure was varied from +200 daPa to -400 daPa with a pump speed of 50 daPa/s. The data were digitized and transferred to a personal computer to be printed and to be added to a database.

The files were retrieved of all patients who underwent surgery for isolated ossicular reconstruction with intact tympanic membrane over the last 3 years. Sixteen cases were selected that were fully documented, i.e. with 678 Hz tympanometry, CT scan and exploratory tympanotomy. In all cases the middle ear disruption was visually confirmed at the time of the operation. The group consisted of 6 female and 10 male subjects. The mean age was 33 years (range : 10-60 years).

The 226 Hz admittance tympanogram, the 678 Hz susceptance-conductance tympanograms and the CT-imaging were scored either as normal or as abnormal using the following criteria :

For the 226 Hz tympanogram, the criterion for abnormality was based on the shape of the tympanogram and on the static admittance magnitude. W-shaped tympanograms were scored as abnormal as well as bell-shaped tympanograms (Jerger type A (8)) having static admittance values at 226 Hz that exceeded 1.75 mmho (based on normal values obtained for adults, per WILSON *et al.* (9)).

The 678 Hz tympanograms were scored using the criteria proposed by CRETEN *et al.* (7) and Van de Heyning *et al.* (5). Normal patterns of susceptance-conductance are :

- Type 1B1G : both B1 and G1 are bell-shaped
- Type 3B1G : B1 displays 3 extrema and G1 is bell-shaped
- Type 3B3G : both B1 and G1 have 3 extrema and :
  - The pressure interval between the outer B1 maxima is smaller then 75 daPa

- The G1 maxima fall within the pressure interval of the B1 maxima
- The central minima occur at the same pressure
- Type 5B3G : B1 has 5 extrema while G1 shows 3 extrema and :
  - The pressure interval between the outer B1 maxima is smaller then 100 daPa
  - The G1 maxima fall within the pressure interval of the B1 maxima
  - The central extrema occur at the same pressure

For the CT-scan the judgment of the radiologist together with the ENT-specialist was used for scoring.

All patients underwent ossicular reconstruction (ossiculoplasty). The reconstruction technique used was either a figure-8 incudoplasty according to MARQUET or a collumellar reconstruction (fig. 1 and 2) (10).

## Analysis of the results

Table 1 summarizes the individual patient data.

226 Hz tympanograms.

Table 1

Individual oto-admittance data for all patients including : the 678 Hz tympanometry classification, the pressure interval between the outer susceptance peaks, the 226 Hz tympanometric shape (and Jerger classification), static admittance values and CT imaging scoring (+ : extra superimposed peak ; N.A. : not available).

Patient	678 Hz B/G class	P interval [daPa]	226 Hz shape (Jerger)	Static Admittance [ml]	CT imaging
1	5B3G	100	W		Normal
2	3B1G	30	Bell (Ad)	2.6	Normal
3	3B3G +	110	Bell (Ad)	1.8	Abnormal
4	3B3G	75	Bell (A)	1.5	Abnormal
5	5B3G	350	W		Abnormal
6	3B3G	100	Bell (As)	0.4	Abnormal
7	3B3G	105	Bell (A)	1.4	Abnormal
8	3B3G +	130	Bell (A)	1.3	Abnormal
9	3B3G +	140	Bell (Ad)	4.4	Abnormal
10	3B3G	150	Bell (Ad)	2.7	Abnormal
11	3B3G +	160	N.A		Normal
12	3B1G	40	Bell (A)	1.2	Abnormal
13	3B3G +	95	Bell (A)	1.1	Abnormal
14	5B3G +	200	Bell (A)	0.5	Abnormal
15	3B3G +	200	Bell (A)	1.2	Abnormal
16	5B3G	100	N.A		Abnormal

The static admittance in normal adults (Jerger type A (8)) falls within the interval of 0.50 to 1.75 mmho (9). In our series 226 Hz tympanometry was available in only 14 out of the 16 cases.

Twelve patients presented a bell-shaped tympanogram. The median value of the static admittance in this group was 1.26 mmho and the range was 0.40 to 4.40 mmho. Only 4 out of the 12 cases presented an abnormally high static admittance value using a 226 Hz probe frequency.

In addition 2 patients presented an abnormal W-pattern.

So only 43% (6/14) of the tympanograms could be qualified as abnormal using the 226 Hz criteria.

678 Hz susceptance-conductance tympanograms.

Two patients presented a 3B1G type of tympanogram. CRETEN *et al.* (7) classify this type as normal. In these 2 cases the 678 Hz tympanometry was accordingly false normal. In the first 3B1G case

there was a clear lysis of the crus longum of the incus. This pathology was possibly masked by low admittance components that were observed : a sclerotic tympanum and fibrotic tissue going from the malleus to the promontory. In the second case there was an almost complete lysis of the incus and no low admittance factors.

Ten patients presented a 3B3G type of tympanogram with a pressure interval between the two outer susceptance maxima that was equal or higher than 75 daPa. The median pressure interval in this group was 110 daPa with a range from 75 to 200 daPa. All these 3B3G cases were correctly labeled as pathologic using the 678 Hz tympanometry. An example of this type of tympanogram is given in figure 3. Figure 4 shows the tympanogram of the same patient as in figure 3 but after ossicular reconstruction. As can be seen when comparing figure 3 with figure 4, the tympanogram changed from type 3B3G to 3B1G

and the pressure interval between the two outer susceptance maxima dropped below 75 daPa.

Four patients presented a 5B3G type of tympanogram with a pressure interval between the two outer susceptance maxima that was equal or higher than 100 daPa. The median value for this pressure interval was found to be 150 daPa with a range of 100 to 350 daPa. All of these 5B3G cases were also correctly labeled as pathologic using the 678 Hz tympanometry.

CT imaging of the ossicular system.

In most cases (13 out of 16) the middle ear pathology was visible on the CT scan and was correctly identified by the radiologist. In 3 cases however the middle ear pathology was not identified and these cases were falsely labeled as normal.

In the first case, visual inspection at the time of the operation showed an incudostapedial joint

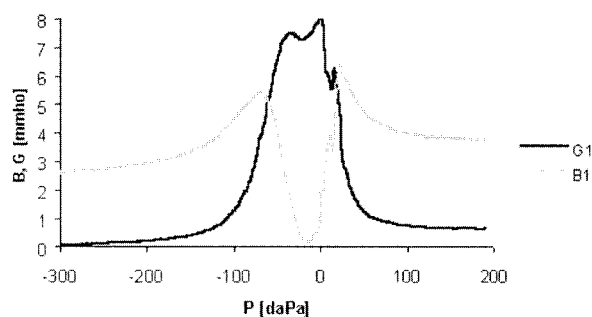


Fig. 3

Example of a pathological 3B3G tympanogram. Pressure interval between the outer susceptance maxima  $\geq 75$  daPa.

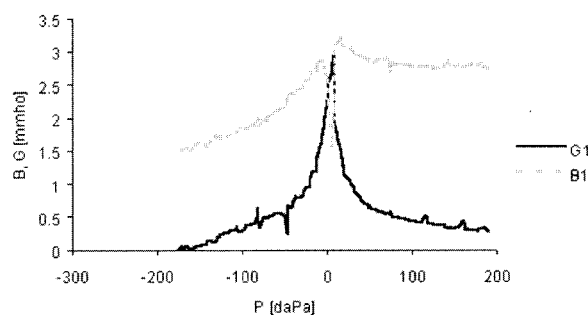


Fig. 4

Tympanogram from the same ear as in figure 3 but after ossicular reconstruction. The tympanogram became a normal 3B1G type of tympanogram.

Table 2

Predictive values of 678 Hz multicomponent tympanometry compared to the predictive value of CT scan

		678 Hz Tympanometry : 88% correct	
		Correct	False Normal
CT scan ossicles : 81% correct	Correct	12	1
	False Normal	2	1

disrupture with a lysis of the stapedial arch. The 678 Hz tympanogram in this case was a 5B3G type with a pressure interval of 105 daPa (correctly labeled as pathological).

In the second case, visual inspection showed a clear lysis of the crus longum of the incus. The 678 Hz tympanogram (3B1G) also incorrectly labeled this case as normal.

In the third case, visual inspection showed a complete incudostapedial joint disruption. The 678 Hz tympanogram in this case was a 3B3G type with a pressure interval of 160 daPa (correctly labeled as pathological).

Table 2 summarizes these results.

## Discussion

The data in this retrospective study show that the classic static admittance value obtained with a

probe frequency of 226 Hz is not sensitive enough to identify most of the ossicular disruptions (only 43% of the cases).

The predictive value of the CT-imaging and 678 Hz B-G tympanometry clearly exceeds that of the 226 Hz static admittance (81 and 88% correct prediction respectively).

The diagnosis of an ossicular disruption is often a challenge. The patients' symptoms are mainly hearing loss. The audiogram shows a conductive hearing loss and classic 226 Hz tympanometry shows close to normal compliance with a normal middle ear pressure while stapes reflexes are absent. The most probable diagnosis will be otosclerosis in this case (prevalence). But for the prognostic counseling of the operation and the availability of reconstructive material at the time of the operation it can be of great importance to exclude the differential diagno-

sis of ossicular disruption. As the results show, this can be done by means of CT scan or two-component 678 Hz tympanometry.

CT scan has some disadvantages compared to 678 Hz tympanometry: it is more expensive, possible hazardous (X-rays), more time consuming and it requires the evaluation by an experienced radiologist.

Two-component 678 Hz tympanometry seems to be a valid alternative option as a clinical tool in the differential diagnosis of ossicular disruptions. This technique is relatively easily available on today's apparatus. The only possible problem arising using this test can be the number of false positive cases. Since this study is a retrospective one, it holds no figures on the number of false positive cases.

## Conclusions

This study clearly indicates that two-component (B and G) tympanometry at higher probe frequencies (678 Hz) performs much better in the identification of abnormal highly admittant middle ears, compared to the classic 226 Hz admittance tympanometry as has been shown by other authors. The

positive predictive value of CT-imaging and 678 Hz two-component tympanometry is of the same order of magnitude. In our series, the 678 Hz tympanometry scored even better than CT-imaging of the middle ear ossicles.

## References

1. MARQUET J., VAN CAMP K. J., CRETEN W. L., DECRAEMER W. F., WOLFF H. B. Topics in Physics and middle ear surgery. *Acta ORL Belgica*, **27** (3) : 147-308, 1973.
2. VAN CAMP K. J., MARGOLIS R. H., WILSON R. H., CRETEN W. L., SHANKS J. E. Principles of tympanometry. *ASHA Monogr.*, Mar ; (24) : 1-88, 1986.
3. VAN CAMP K. J., VOGELEER M. A tympanometric approach to otosclerosis. *Scand. Audiol.*, **15** : 109-114, 1986.
4. VANHUYSE V. J., CRETEN W. L., VAN CAMP K. J. On the W-notching of tympanograms. *Scand. Audiol.*, **4** : 45-50, 1975.
5. VAN DE HEYNING P. H., VAN CAMP K. J., CRETEN W. L., VANPEPERSTRAETE P. M. Incudo-stapedial joint pathology : a tympanometric approach. *J. Speech Hear Res.*, **25** : 611-618, 1982.
6. VAN CAMP K. J., CRETEN W. L., VAN DE HEYNING P. H., VANPEPERSTRAETE P. M. Optimizing tympanometric variables for detecting middle ear traumas. *Scand. Audiol. Suppl.*, **17** : 7-10, 1983.
7. CRETEN W. L., VAN DE HEYNING P. H., VAN CAMP K. J. Immitance audiometry. Normative data at 220 and 660 Hz. *Scand. Audiol.*, **14** : 115-121, 1985.
8. JERGER J. Clinical experience with impedance audiometry. *Arch Otolaryngol*, **92** : 311-324, 1970.
9. WILSON R. H., SHANKS J. E., KAPLAN S. K. Tympanometric changes at 226 Hz and 678 Hz across ten trials and for two directions of ear-canal pressure change. *J. Speech. Hear Res.*, **27** : 257-266, 1984.
10. JANSSENS DE VAREBEKE S., GOVAERTS P. J., SOMERS TH., OFFECIERS F. E. The "two hole" ossiculoplasty technique. *Laryngoscope*, **106** (4) : 507-10, 1996.

P. Govaerts  
University Department of Otolaryngology  
St. Augustinus Hospital  
Oosterveldlaan 24  
B-2610 Antwerp-Wilrijk, Belgium  
E-mail : Dr.govaerts@eargroup.be